



**PATIENT**

Chloe Albano

**SPECIES**

Canine

**BREED**

Terrier Mix

**SEX**

Female Intact

**AGE**

9 months

**WEIGHT**

5.94lbs

**INTERPRETED BY**

Maggie Machen  
Lamy, DVM  
DACVIM (Cardiology)

**IMAGING  
PERFORMED BY**

Pamela Harrigan,  
RDMS

**HOSPITAL NAME**

Mass Veterinary  
Specialty Services

**REFERRING VET**

Dr. Masloski

**INVOICE**

20737

**DATE**

8/25/21

**PRESENTING CLINICAL SIGNS**

History: Referred for evaluation of a heart murmur prior to surgery for an umbilical hernia and spay. No coughing or dyspnea. Good appetite and energy. She was the runt of the litter and has gone into heat once. CV/RESP: pronounced sinus arrhythmia, grade I/VI murmur with PMI left apical area, PSS, lung fields clear. BP: 200mmHg. \*No sedation.

**ECHOCARDIOGRAM FINDINGS**

2D, m-mode, color flow and Doppler imaging is available.

**Left ventricle:** The LV diameter is normal with adequate myocardial function. LV wall thicknesses are normal.

**Left atrium:** The left atrium is normal.

**Mitral valve:** The mitral valve is normal with no prolapse into the left atrial lumen. No mitral regurgitation.

**Aortic valve/Aorta:** The aortic valve is normal in morphology and mobility. Normal aortic outflow velocity; laminar flow. No aortic insufficiency.

**Right ventricle:** Normal right ventricular diameter and morphology indicating no overt evidence of pulmonary arterial hypertension.

**Right atrium:** Normal RA dimension.

**Tricuspid valve:** The tricuspid valve appears normal with no tricuspid regurgitation.

**Pulmonic valve/Pulmonary artery:** The pulmonic valve is normal in morphology and mobility. No pulmonic insufficiency. Normal RVOT velocity; laminar flow.

**Pericardium/other:** No pericardial or pleural effusion noted. No obvious cardiac masses.

**Heart rhythm:** ECG reveals a sinus rhythm with an average HR of 130bpm.

**2-Dimensional Measurements**

Ao diam (cm)	1.1
LA diam (cm)	1.2
LA:Ao (Swe)	1.1
IVS thickness (cm)	0.45
LVID diastole (cm)	1.8
PW thickness (cm)	0.46
LVID systole (cm)	1.0
FS (%)	44

**Doppler Measurements**

PV Vmax (m/s)	0.93
AoV Vmax (m/s)	1.2
MR Vmax (m/s)	NA
TR Vmax (m/s)	NA
TR PG (mmHg)	NA

**INTERPRETATION OF THE FINDINGS**

Overtly normal cardiac structure and function with no cause of the murmur identified in this study. In the absence of significant volume changes (dehydration) or anemia, other possibilities include a physiologic flow murmur only present with elevated heart rates, or a small flow abnormality not seen here. Volume changes that occur with a normal heat cycle can also be at play depending on when the murmur was ausculted. It is reasonable to monitor periodically via recheck echocardiography in the future, particularly should the murmur persist/progress. No significant valvular insufficiencies were noted, and no structural issues identified.



**PATIENT**

Chloe Albano

**SPECIES**

Canine

**BREED**

Terrier Mix

**SEX**

Female Intact

**AGE**

9 months

**WEIGHT**

5.94lbs

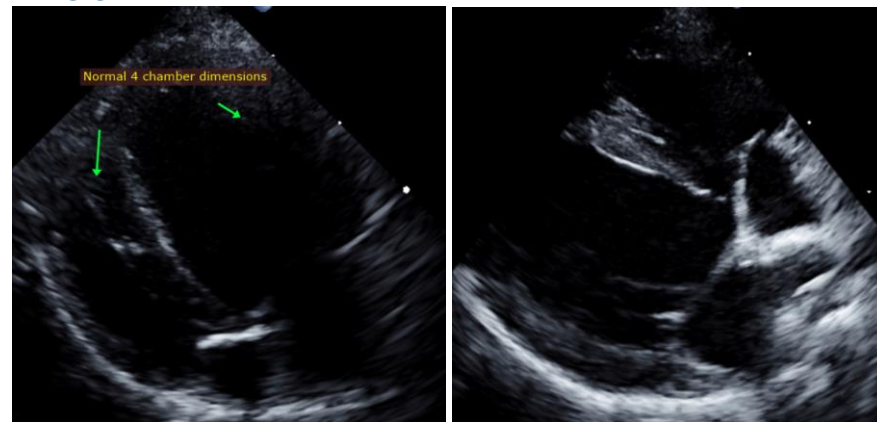
**RECOMMENDATIONS**

- No cardiac medications are indicated at this time. Monitor for any development of cough, labored breathing or exercise intolerance.
- No cardiac contraindication for general anesthesia.

**PLAN**

- Recommend recheck echocardiogram in 12-18 months to screen for progression or development of concurrent cardiac disease that the preexisting murmur may mask.

**IMAGES**



**INTERPRETED BY**

Maggie Machen  
Lamy, DVM  
DACVIM (Cardiology)

The information and recommendations provided are based on the images presented by the referring veterinarian. No evaluation can be communicated regarding pathology that was not visible in the image/video clips provided.

Thank you for this referral. This report was generated using transcription software, and minor dictation errors may be present. If the clinical or image interpretation does not parallel your findings or if I can be of any further assistance, please contact me.

**IMAGING PERFORMED BY**

Pamela Harrigan,  
RDCS

**Maggie Machen Lamy, DVM**  
Diplomate of the American College of Veterinary Internal Medicine (Cardiology)  
info@sonopath.com

**HOSPITAL NAME**

Mass Veterinary  
Specialty Services

**Echocardiogram performed by:** Pamela Harrigan, RDCS  
Pet Animal Ultrasound Service (4paus.com)

**REFERRING VET**

Dr. Masloski

**INVOICE**

20737

**DATE**

8/25/21